

DENTAL RADIOLOGY MADE EASY – Tips and Tricks!

Mary L. Berg, BS, LATG, RVT, VTS(Dentistry), FVTE
Beyond the Crown Veterinary Education
www.btcveted.com
Lawrence, KS

Here are some quick tips for great X-rays every time:

1. You need a diagnostic x-ray – not a perfect x-ray. A diagnostic x-ray allows for the visualization of 2-3 mm of bone around the apex of the root and the level of the alveolar bone. The crown does not need to be on the x-ray.
2. The entire tooth does not need to be on one view. If both roots are visible but on two separate x-rays, it's okay!
3. Get all the teeth in as few views as possible. This saves time and gives a quick survey of the oral cavity. If more detail is needed, additional view should be obtained.
4. Every patient, every time! Not only will this help you become faster at taking x-rays, but it is also better medicine. Remember the patients can't tell us where it hurts.
5. Proper positioning of the animal is key! Place the animal (both dog and cat) in sternal recumbency for the maxillary views and dorsal recumbency for the mandibular. Ensure that the dental arcade is parallel to the table, and the mouth is straight, not tilted in either direction.
6. The sensor (film) should always be placed with the teeth on the very edge of the sensor with the remainder of the sensor inside the mouth, and the sensor should be flat or parallel to the table for maxillary views.
7. High and through the eye on the maxilla!
8. The sensor should be placed parallel to the jaw in the posterior mandibular views (308-311 & 408-411) but returned to a flat or parallel to the table view for the anterior mandibular teeth.
9. Don't fight the tongue for mandibular views!
10. If the x-ray doesn't show what you want to see, determine if the sensor has moved first before changing your tube head.
11. Ideally, the tooth roots should be the same length in the x-ray as in the mouth. If the roots are too long to increase your angle, they are too short, decrease your angle. Think about the position of the sun and your shadow. It will help you correctly adjust your tube head.
12. ALWAYS x-ray missing teeth and pre and post extractions.
13. Practice makes perfect!!!

Radiographs are essential when the following problems are present: periodontal disease, endodontic disease, FORL's, draining tracts, trauma, oral masses, dental abnormalities, and pre, intra, and post-surgical evaluations.

Dental radiograph units are relatively inexpensive. You can check with dental supply companies and purchase used units very reasonably. Medical radiograph machines can be used but are inconvenient, and they don't show the detail necessary to make a definitive diagnosis. Dental radiograph units allow for accurate positioning without having to move the patient. They are compact, maneuverable, have limited settings, and less radiation scatter. The settings for kVp and milliamperage are preset, leaving exposure time as the only adjustable setting.

As with all radiation, it is important to observe radiation safety guidelines. The amount of radiation should be kept to a minimum. If possible, step outside of the room but if it isn't possible stay at least 6 feet away and out of the line of the beam. Always wear your film badge. There is a full range of positioning devices available to help keep the film in place. A gauze 4X4 works very well, are disposable and inexpensive.

Proper patient and sensor positioning will make taking dental x-rays easier. The patient should be placed in sternal recumbency with the maxillary arch parallel to the table for the maxillary views and dorsal recumbency with the mandibular arch parallel to the table for the mandibular views. The sensor should always be placed in the mouth flat (or parallel to the table) with the cord coming out the front of the mouth for all views except the posterior mandibular teeth on dogs (308 to 311 and 408 to 411), where the sensor is placed parallel the mandible.

A full radiographic survey will include; anterior maxilla, anterior mandible, posterior maxilla (left & right), posterior mandible (left & right). There may need to be a need for additional views for specific teeth or in larger animals.

There are two intraoral radiograph techniques commonly utilized in veterinary dentistry. The simplest is the parallel technique and is used in the caudal mandible. This view will include the molars and caudal premolars. In the parallel technique, the sensor is placed parallel to the mandible, and the beam is directed at a 90-degree angle to the sensor.

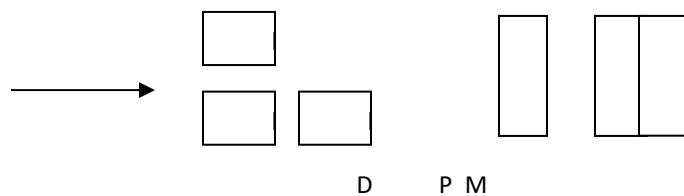
The other technique is the bisecting angle. The bisecting angle minimizes distortions of the teeth. The bisecting angle is used for the anterior teeth, maxilla, and mandible, the posterior maxilla teeth. In this technique, the beam is aimed at the imaginary line bisecting the plane of the tooth and the plane of the film.



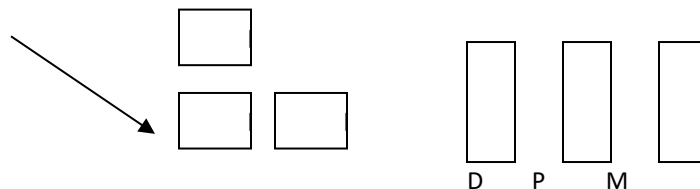
If the beam is not perpendicular to the bisecting angle, the image of the tooth will be distorted. If the angle is too low, it will cause elongation and too high it will cause foreshortening. However, since the bisecting angle technique can be difficult to understand for many individuals, a method that uses the angles on the tube head to assist in positioning is much easier to understand. This technique requires the patient to be properly positioned as state earlier in sternal or dorsal recumbency. See the Easy Guide to Dental X-ray Positioning (available upon request)

The maxillary P4 is a three rooted tooth. If you use the bisecting angle technique, the palatal root will be superimposed behind the mesiobuccal root. Using the SLOB rule will result in viewing all three roots. (Same Lingual, Opposite Buccal) The tube head is shifted slightly rostral or caudal to visualize all three roots. If the tube head is moved caudally, the palatal or lingual root will be most caudal on the radiograph. If the tube head is moved rostrally, the lingual root will be the most rostral root on the radiograph. Remember, the tube head pulls the palatal root towards itself. TPP = Tubehead Pulls Palatal

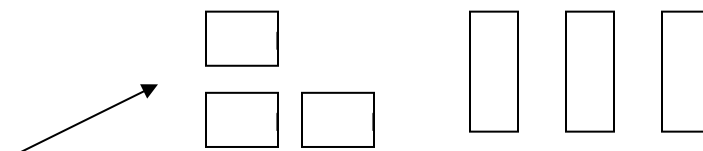
Standard bisecting angle:



SLOB Rule tubehead caudal



SLOB Rule tubehead rostral



In cats, radiographs of the maxillary premolars and molars utilizing the bisecting angle technique result in the superimposition of the zygomatic arch or the apex of the root. With the advancement in digital x-ray technology, it is not as crucial that the zygomatic arch avoided as the apexes of the roots can be seen through the arch.

References: Available upon request.